



gold standard
Cancer Care
HCA Hospitals

hcacancercare.co.uk

THE HARLEY STREET CLINIC

THE LISTER HOSPITAL
chelsea

London Bridge Hospital

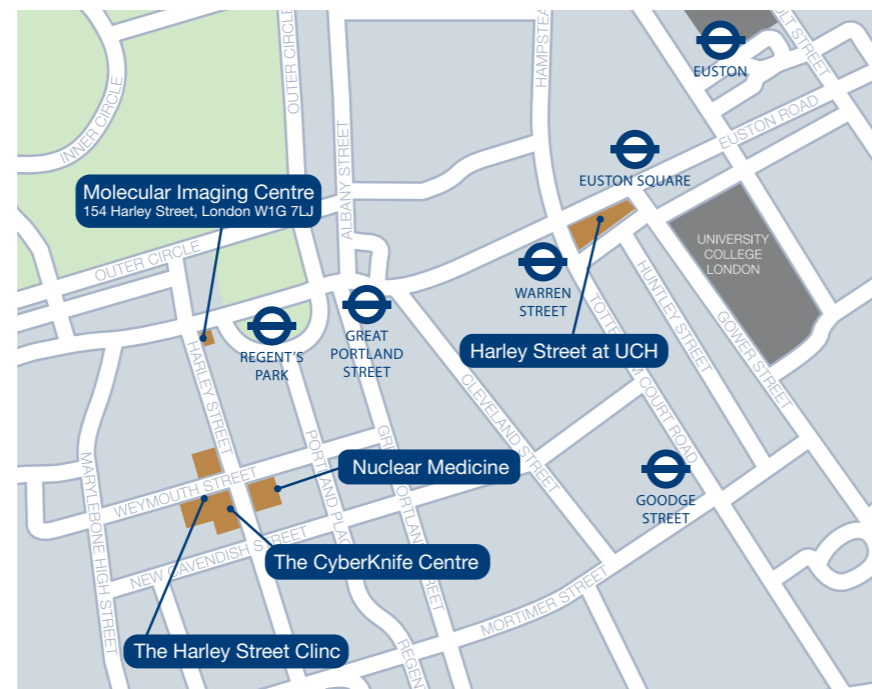The Portland Hospital
for Women and Children

THE PRINCESS GRACE HOSPITAL

The Wellington Hospital

HARLEY STREET AT UCH

HCA - London's No.1 private hospital group



The CyberKnife Centre
81 Harley Street
London W1G 8PP

Tel: 020 7034 8588
cyberknifecentre.london.co.uk

CASE STUDY
**Non-Invasive Stereotactic
Radiosurgical Treatment of
Non-Small cell Lung Cancer**



THE
CYBERKNIFE CENTRE
LONDON

CYBER KNIFE
CENTER OF MIAMI

Radiation Oncologist: Hoke Han, M.D., **Thoracic Surgeon:** Mark Block, M.D., **Physicists:** Alberto de la Zerda, Ph.D., Elizabeth Bossart, Ph.D., **Dosimetrist:** Vidya Persaud, **Therapists:** April Hildebrand, Steve Reyes, **CyberKnife Center:** CyberKnife Center of Miami



HCA - London's premier private cancer network

Demographics

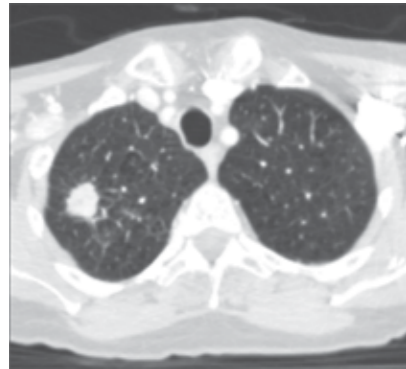
Sex: Male
Age: 75 years
Histology: Meningioma

Clinical History

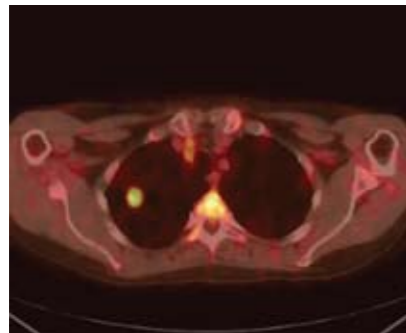
Referred by: Neurosurgery
Previous Treatment: Previously resected

Treatment Details

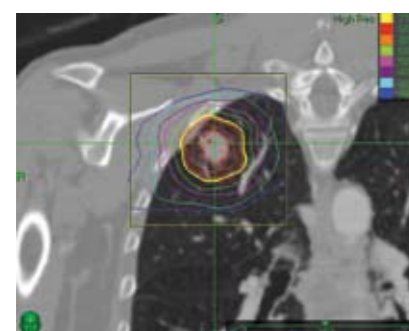
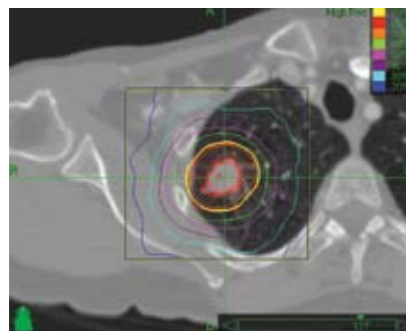
| | | | |
|---------------------------|----------------------|----------------------|---|
| Gross Tumor Volume (GTV): | 3.60 cm ² | Number of Fractions: | 3 fractions of 20 Gy |
| Imaging Technique(s): | CT | Treatment Time: | Mean 57 min/fraction |
| Rx Dose & Isodose: | 60 Gy to 75% | Tracking Method: | Synchrony with Xsight Lung (No fiducials) |
| Conformality Index (PTV): | 1.15 | Collimator(s): | 10 mm |
| Number of beams: | 148 beams/fraction | Tumor Coverage: | 96.7% |
| Homogeneity Index: | 1.33 | | |



Pre-treatment diagnostic CT axial image demonstrating 1.8 cm x 1.6 cm x 1.7 cm lesion in the upper lobe of the right lung.



Pre-treatment diagnostic PET-CT axial image demonstrating increased SUV uptake in the right upper lobe lesion.



Axial and coronal treatment planning images showing gross tumor volume (GTV, red) and planning tumor volume (PTV, red). The 75% prescription isodose line is shown in yellow.

Case History

A 72-year-old female smoker with a history of COPD presented with new onset of shortness of breath after walking less than 50 feet. No other symptoms were noted. Further evaluation by CT imaging demonstrated a new 1.8 cm x 1.6 cm x 1.7 cm lesion in the upper lobe of the right lung (RUL). Follow-up PET-CT imaging demonstrated increased SUV uptake of 5.2 within the lesion. No other regions of SUV uptake were noted. No increased SUV uptake within the nodes of the mediastinum was noted. Biopsy results demonstrated lesion to be consistent with NSCLC. Given the PET-CT and biopsy results, this patient was diagnosed with Stage 1a non-small cell lung cancer (Stage T1N0M0 NSCLC). The patient's pre-treatment pulmonary function tests (PFTs) were below normal limits secondary to her history of smoking and advanced COPD. Her maximum oxygen consumption was 0.983 L/min (62% of predicted); normalized to body weight, her maximum oxygen consumption was 17.6 ML/KG/min (62% of predicted). The patient's maximum minute ventilation at maximum exercise was 71% of predicted.

CyberKnife® Treatment Rationale

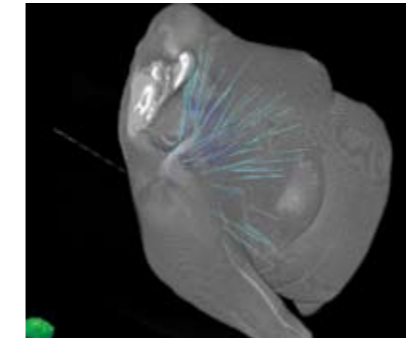
When possible, Stage IA NSCLC is treated by primary surgical resection (lobectomy or segmentectomy).^{1,2} Conventional radiation therapy and chemotherapy have been reserved for patients who refuse surgery or who are deemed medically inoperable because of associated comorbidities. In recent years improved tumor control with relatively few complications has been achieved using high-dose, hypofractionated stereotactic radiation delivery.³⁻⁸ This patient was a poor surgical candidate because of her depressed PFTs and her history of advanced COPD. Given the potential for sub-optimal outcomes of conventional radiation therapy, the inclusion of large volumes of normal lung tissue within the radiation field, and the patient's prior history of external beam radiation to the right breast for treatment of her breast cancer in the past, CyberKnife® Radiosurgery using fiducial-free Xsight® Lung Tumor Tracking was chosen to deliver focal, high-dose, hypofractionated radiation treatment that maximizes dose to this patient's lung tumor and minimizes dose to surrounding normal tissue. Xsight Lung is a non-invasive method that allows the CyberKnife System to track tumor motion throughout treatment without the need for implantation of metal fiducials in the lung tumor.

Planning Process

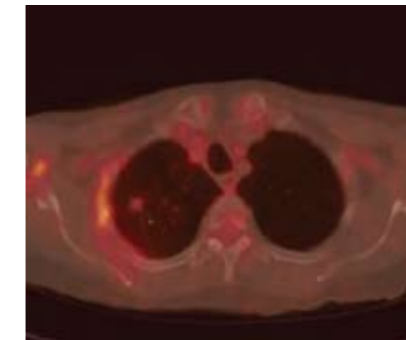
The patient's only preparation for treatment was a planning CT scan (with breath holding) to identify the tumor target. No fiducials or implantation of any markers was required given the use of the Xsight® Lung technology. Following completion of imaging, the lesion was outlined on the scans resulting in a gross tumor volume of 3.60 cm³. A treatment plan was created to deliver 60 Gy in 3 fractions to the 75% isodose line 8-mm tumor margins to encompass microscopic extension (6 mm) and targeting uncertainties (2 mm), using the 20-mm and 30-mm collimators.

Treatment Delivery

The patient underwent CyberKnife® treatment in an average of 57 minutes/fraction using 148 beams/fraction. The prescribed dose covered 100% of the tumor volume with a homogeneity index of 1.33 and a conformality index of 1.15 for the PTV. The patient tolerated the procedure well.



Three-dimensional reconstruction of beam geometries.



Outcome and Follow-Up

Four months after CyberKnife treatment CT imaging revealed an interval decrease in the size of the RUL lesion, which decreased in size to less than 1 cm in maximum dimension (0.9 cm x 0.8 cm x 0.9 cm). There were no noted acute complications. The patient remained asymptomatic with stable post-treatment PFTs.

Conclusion and CyberKnife® Advantages

- This patient had an excellent initial outcome with the CyberKnife® System using Xsight® Lung Tumor Tracking System. The patient was able to undergo treatment completely non-invasively without implanted fiducials or markers.
- The Xsight Lung Tumor Tracking System allows the CyberKnife System to track tumor motion continuously throughout treatment, minimizing irradiation of surrounding tissue and maximizing dose to the tumor, thus decreasing the risk of complications such as radiation pneumonitis.
- No acute side effects or change in post-treatment PFTs were noted.
- The CyberKnife System provides an excellent, completely non-invasive treatment option for patients with lung tumors who are poor surgical candidates because of associated medical conditions and are unable to tolerate any degree of invasiveness in the treatment of their cancer.

CyberKnife Center of Miami

The CyberKnife Center of Miami, operational in 2003, was the first CyberKnife system on the South-East coast. The center was among the first to implement Xsight Spine and Xsight Lung treatment modalities. Over 700 patients with a wide range of clinical indications in various anatomical locations have been treated successfully. Much of the center's clinical and research work has been published.⁹⁻¹¹

References

1. Handy JR, Jr., Asaph JW, Skokan L, et al. What happens to patients undergoing lung cancer surgery? Outcomes and quality of life before and after surgery. *Chest* 2002;122:21-30.
2. Jones DR, Detterbeck FC. Surgery for stage I nonsmall cell lung cancer. In: Detterbeck FC, Rivera MP, Socinski MA, et al., editors. *Diagnosis and treatment of lung cancer: An evidence-based guide for the practicing clinician*. Philadelphia: W.B. Saunders; 2001. pp. 177-190.
3. McGarry RC, Papiez L, Williams M, et al. Stereotactic body radiation therapy of early-stage non-small-cell lung carcinoma: phase I study. *Int J Radiat Oncol Biol Phys* 2005;63:1010-1015.
4. Onishi H, Araki T, Shirato H, et al. Stereotactic hypofractionated high-dose irradiation for stage I nonsmall cell lung carcinoma: clinical outcomes in 245 subjects in a Japanese multiinstitutional study. *Cancer* 2004;101:1623-1631.
5. Timmerman R, McGarry R, Yiannoutsos C, et al. Excessive toxicity when treating central tumors in a phase II study of stereotactic body radiation therapy for medically inoperable early-stage lung cancer. *J Clin Oncol* 2006;24:4833-4839.
6. Brown WT, Wu X, Amendola B, et al. Treatment of early non-small cell lung cancer, Stage IA, by image-guided robotic stereotactic radioablation – Cyberknife. *The Cancer Journal* 2007; 13(2):87-94
7. Brown WT, Wu X, Fayad F, et al. CyberKnife® Radiosurgery for Stage I Lung Cancer: Results at 36 Months. *Clinical Lung Cancer* 2007; 8(8): 488-492.
8. Brown WT, Wu X, Wen BC, et al. Early results of CyberKnife image guided robotic stereotactic radiosurgery for treatment of lung tumors. *Computer Aided Surgery*. Sept 2007;12(5):1-9.
9. Wu X, Fu D, De la Zerda A, et al. Patient Alignment and Target Tracking in Radiosurgery of Soft-Tissue Tumors Using Combined Fiducial and Skeletal Structures Tracking Techniques. *Robotic Radiosurgery Volume II: Cyberknife Society Press; 2007: 31-36.*
10. Brown WT, Wu X, Amendola BE, et al. Initial experience treating lung tumors with the Cyberknife. *Robotic Radiosurgery Volume II. The Cyberknife Society Press; 2007: 155-164.*
11. Brown WT, Perman M, Wu X, et al. Image-guided robotic stereotactic radiosurgery of lung tumors. *Robotic Radiosurgery Volume I: Cyberknife Society Press; 2005: 255-268.*